

## Genitourinary tuberculosis - a rare presentation of a still frequent infection in renal transplant recipients

Tuberculose genitourinária - uma apresentação rara de uma infecção ainda frequente nos doentes transplantados renais

### Authors

Natacha Jardim Rodrigues <sup>1</sup>

Laila Viana <sup>2</sup>

Juliana B. Mansur <sup>2,3</sup>

Hélio Tedesco-Silva <sup>2,3</sup>

José Osmar Medina

Pestana <sup>2,3</sup>

<sup>1</sup> Centro Hospitalar Lisboa Norte, Lisboa.

<sup>2</sup> Universidade Federal de São Paulo.

<sup>3</sup> Hospital do Rim, São Paulo.

### ABSTRACT

*Mycobacterium tuberculosis* infection in renal transplant recipients is associated with significant morbidity and mortality. Genitourinary tuberculosis is a less frequent presentation and a high level of suspicion is needed to avoid treatment delay. Management is challenging due to the interaction of calcineurin inhibitors with antituberculous medications and the known side effects of these drugs, with higher prevalence in this population. The authors present a case of a renal transplant recipient with urinary and constitutional symptoms whom is diagnosed with tuberculosis after a prostatic biopsy in an already disseminated stage and develops hepatotoxicity to antituberculous therapy.

**Keywords:** iatrogenic disease; kidney transplantation; primary treatment; tuberculosis, urogenital.

### RESUMO

A infecção por *Mycobacterium tuberculosis* nos doentes transplantados renais está associada a morbidade e mortalidade significativas. A tuberculose genitourinária é uma apresentação menos frequente desta infecção e é necessário um elevado índice de suspeição para evitar atraso no diagnóstico e tratamento. A abordagem terapêutica é desafiante dada a interação dos inibidores da calcineurina com os tuberculostáticos e os vários efeitos secundários destes fármacos, mais prevalentes nesta população. Os autores apresentam um caso de um doente transplantado renal com sintomas urinários e constitucionais que é diagnosticado com tuberculose após biópsia prostática e que desenvolve hepatotoxicidade à terapêutica.

**Palavras-chave:** doença iatrogênica; transplante de rim; tratamento primário; tuberculose urogenital.

### INTRODUCTION

Tuberculosis (TB) is currently estimated to affect 8 to 9 millions of people worldwide annually, resulting in death in 20% of patients. The majority of cases are found in Asian countries. In Brazil, the number of new cases is estimated in 100.000/year.<sup>1</sup>

The incidence of TB in renal transplant recipients (RTRs) varies according to geographic location between 1.2% to 6.4% up to 15% in areas of high-level endemicity.<sup>2,3</sup> Immunosuppression schemes impair cellular immune function compromising CD4+ T lymphocytes, which play a key role in the immune response to *M. tuberculosis* by contacting to mononuclear phagocytes and influencing their differentiation and activation status for granuloma formation<sup>1</sup> and

consequently promotes the development of the intracellular agent bacillus of Koch. Also, the lower response of the immunity system of RTRs makes the immunological diagnosis of TB especially difficult.<sup>1</sup>

In RTRs, TB manifests mainly by reactivation of latent infection<sup>2,4</sup> although cases of new infection and donor's transmission have been reported.<sup>5,6</sup> Extrapulmonary or disseminated TB represent one third of cases of active TB in RTRs<sup>2,7</sup> and the majority of cases are diagnosed in the first year of transplant.<sup>8</sup> Genitourinary tuberculosis is among the uncommon presentations described with an incidence of 7,1-15%<sup>2,9</sup> and usually presents with multiple parenchymatous renal foci, less lesions of the collecting system and can manifest only with fever and sterile leukocyturia.<sup>10</sup>

Submitted on: 12/6/2016.

Approved on: 1/17/2017.

### Correspondence to:

Natacha J. Rodrigues.

Centro Hospitalar Lisboa

Norte.

Avenida Egas Moniz, Lisboa,

Portugal.

CEP: 1649-035

E-mail: rodrigues120@hotmail.com

DOI: 10.5935/0101-2800.20170040

In RTRs with history of untreated TB, contact with a patient with active TB or with chest radiography findings compatible with untreated TB, treatment of latent TB is well established in the KDIGO Consensus.<sup>11</sup> The drug of choice in these situations is isoniazid (300 mg/day) supplemented with vitamin B6 for nine months.<sup>2,12,13</sup> Unfortunately, treatment of active TB in RTRs is not consensual due to the known interaction of rifamycins with calcineurin inhibitors, the known higher side-effects of antituberculosis drugs in RTRs and the unknown optimal duration of treatment.

We present a case of a RTR with urinary and constitutional symptoms whom we diagnosed with genitourinary TB and developed hepatotoxicity to antituberculous therapy.

### CASE REPORT

A 62-year-old caucasian renal transplant recipient male was admitted in our unit with polaquiuria, dysuria and fatigue for the last three days.

He transplanted fifteen months ago, and his immunosuppression regimen comprises tacrolimus, mycophenolate mofetil and prednisone. His baseline creatinine was 1,7 mg/dl and had history of dyslipidaemia and severe aortic and mitral insufficiency.

Physical examination was unremarkable and laboratory findings revealed a 27,3% haematocrit, white-cell count of 15200/mm<sup>2</sup>, platelet count of 290000/mm<sup>2</sup>, reactive C protein 15,4 mg/dl and serum creatinine of 2,54 mg/dl. Urinalysis showed leucocytes 15 cells/field. Cultures were collected and he was started on Ceftriaxone.

On the third day of admission urinary symptoms had diminished but he had fever (38,9°C). The urinary culture was negative for infection but we decided to keep ceftriaxone while waiting for blood culture results. We collected samples for fungal blood cultures, mycobacterial blood cultures, latex agglutination for cryptococcal antigen. Laboratory findings showed a white-cell count of 16000/mm<sup>2</sup>, reactive C protein of 15,04 mg/dL, serum creatinine of 2,39 mg/dL, ALT 34 U/L and AST 19 U/L. An abdominal CT scan showed augmented retroperitoneal lymph nodes and an augmented prostatic volume associated to heterogeneous density of prostatic parenchyma with hypodense regions suggestive of prostatic abscesses.

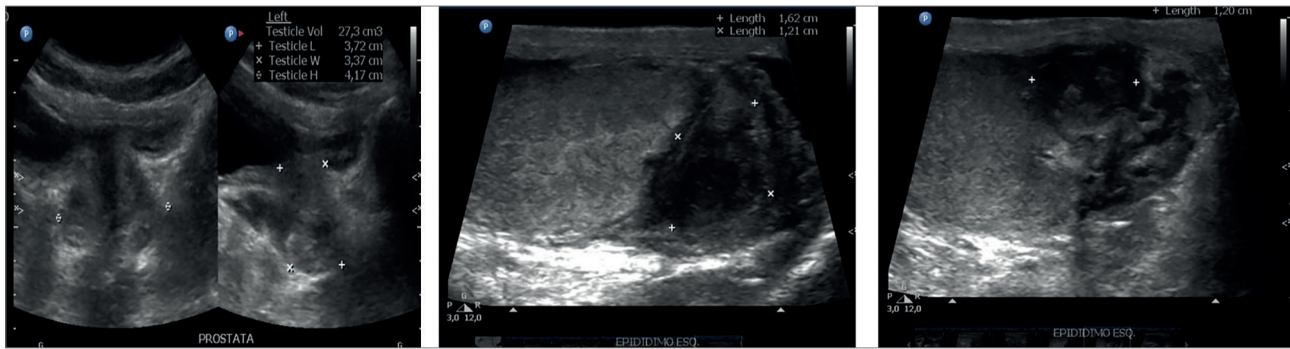
The patient was submitted to a thorough genital examination. His left testicle presented a solid mass on the upper portion, contiguous with a thick epididymis, and the patient complained of pain to palpation. On rectal examination, prostate was enlarged, had a smooth surface with a fluctuation in the central region of 2 cm diameter. A testicular ultrasound with Doppler showed an augmented left epididymis with heterogeneous structure in caudal region with a hypoecogenic collection of 16x12 mm and diffuse augmented flux peripheral to the collection. These findings were compatible with a left epididymitis with distal abscess (Figure 1).

A transrectal prostatic ultrasound showed a lobulated prostate with an estimated volume of 54 cm<sup>3</sup>, hypoecogenic collections were found in internal glands with 25x17 mm on the right side and 25x24 mm on the left side. Seminal vesicles showed hypoecogenic collections of 23 cm<sup>3</sup> on the right side and 5 cm<sup>3</sup> on the left side. Prostatic collections were punctuated and sent to microbiological analysis. Tumoral markers were collected. At this time white-cell count had dropped to 8000/mm<sup>2</sup> but reactive C protein was 18,6 mg/dl and serum creatinine was 2,25 mg/dl.

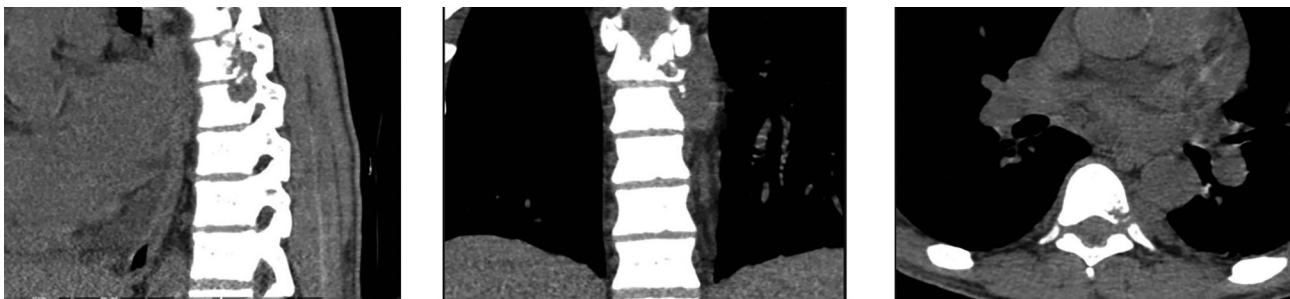The next day he complained of leg weakness being only able to walk with help of the staff, urinary incontinence and back pain. On physical examination muscle force was 4-/5 on the proximal inferior limbs and 4+/5 on the distal inferior limbs. A thoracic spine CT scan revealed remodelling of the vertebral corpus and pediculum of D8 and erosion of vertebral corpus of D7 with obliteration of the foramen D7-D8 and D8-D9 (Figure 2). He was put on corticosteroids. Alcohol acid resistant bacilli were detected on the prostatic drainage secretion. Antituberculosis therapy was started - rifampicin, isoniazid, pyrazinamide and ethambutol (RIPE scheme). He showed clinical improvement of the neurological symptoms.

The patient evolved with remission of both clinical and laboratory findings. On third day of RIPE he was afebrile and showed considerable improvement of the neurological findings, his reactive C protein dropped to 4 mg/dl, serum creatinine was 1,56 mg/dl but AST was 245 IU/L and ALT 269 IU/L. On sixth day of RIPE he had levels of AST of 1100 IU/L and ALT of 1200 IU/L with no signs of obstructive pathology. We suspended RIPE assuming toxic hepatitis secondary

**Figure 1.** Testicular ultrasound showing an augmented left epididymis with heterogeneous structure in caudal region with a hypoecogenic collection of 16x12 mm.



**Figure 2.** Thoracic spine CT scan revealing coalescent nodular formations of soft tissue density at D7 and D8 level in left paravertebral region with 3,8 x 2,8 cm responsible for remodelling of the vertebral corpus and pediculum of D8 and erosion of vertebral corpus of D7 with obliteration on the left side of the foramen D7-D8 and D8-D9.



to treatment. After four days of suspension hepatic transaminases were near normal but he presented fever (38°C) and chills. An alternative scheme was started - amikacin, ethambutol e levofloxacin and three days later rifampicin was added. Three days after that isoniazid replaced amikacin.

Prostatic and testicular ultrasound were repeated after six weeks of antituberculosis therapy and showed a reduction of the prostatic volume to 18 cm<sup>3</sup> with preserved shape and contour with a slight heterogeneous ecostructure, normal seminal vesicles, and an augmented left epididymis with heterogeneous structure in caudal region.

The patient was discharged and follow-up was maintained in our outpatient unit (Table 1).

## DISCUSSION

When a RTR with a known serious cardiac condition presented with urinary symptoms, fatigue and weakness was easily interpreted as a urinary tract infection and decompensating heart failure. On the other hand, the augmented retroperitoneal lymph nodes and nocturnal fever could be in relation with an eventual linfoproliferative post-transplant disease and even prostatic ultrasound findings

suggestive of abscesses could have other agents besides *M. tuberculosis* commonly responsible for prostatic abscesses such as *Escherichia coli*, *Neisseria gonorrhoeae* or *Staphylococcus aureus*.

Genitourinary TB is described in a small portion of TB cases in RTRs. The risk factors for TB after transplantation were presented by the Consensus Statement of the Group for Study of Infection in Transplant Recipients (GESITRA).<sup>8</sup> It emphasises factors such anti-T lymphocyte antibodies therapy, graft rejection therapy, history of exposure to *Mycobacterium tuberculosis*, *diabetes mellitus*, Hepatitis C infections, chronic liver disease and other coexisting infections such as profound mycoses, *Cytomegalovirus*, *Pneumocystis jiroveci* or *Nocardia pneumonia*.

According to literature, in patients with local nonsevere forms of TB treatment with rifamycins should be avoided because of the drug interference with calcineurin inhibitors. The TBNET group and the European Society of Clinical Microbiology and Infectious Diseases suggest a three-drug regimen of isoniazid, ethambutol and pyrazinamide or levofloxacin for two months followed by two-drug regimen of isoniazid and ethambutol or pyrazinamide for 12-18 months.<sup>14</sup> In severe or disseminated forms

**TABLE 1** TEMPORAL EVOLUTION OF LABORATORY AND IMAGING FINDINGS

	Day 1	Day 3	Day 6	Day 13/Day 6 of RIPE	Day 54/ Day 48 total antituberculosis therapy
Hematocrit (%)	27.3	29	28.6	32	35
White-cell count(/mm <sup>2</sup> )	15200	16000	15400	8000	6500
Platelet count (/mm <sup>2</sup> )	290000	220000	240000	270000	320000
reactive C protein (mg/dl)	15.4	15.04	18.6	3.4	1.2
Serum creatinine (mg/dl)	2.54	2.4	2.25	1.56	1.5
AST/ALT (U/L)		19/34		1100/1200	24/36
Urinalysis	15 leucocytes				normal
Imaging		Pelvic CT scan: augmented retroperitoneal lymph nodes, prostate 54 cm <sup>3</sup> with prostatic abscesses; Testicular ultrasound with Doppler: left epididymitis with distal abscess.	Microbiology of prostatic drainage: Alcohol acid resistant bacilli	Abdominal ultrasound: normal	Prostatic and testicular ultrasound prostatic volume 18 cm <sup>3</sup> , preserved shape, slight heterogeneous ecostructure, normal seminal vesicles, augmented left epididymis with heterogeneous structure in caudal region.

the Spanish Network of Infection in Transplantation defends a rifamycin-containing regimen due to potent sterilizing activity of such regimens.<sup>8</sup>

Our patient had both genitourinary and bone involvement so he was started on a rifamycin-containing regimen with rifampicin, isoniazid, pyrazinamide and ethambutol. The serum concentration of the calcineurin inhibitor was closely monitored and dose adjustment was made accordingly. Some authors suggest a reduction of immunosuppression at the beginning of the treatment. We decided not to reduce immunosuppression based in some reports of immune reconstitution inflammatory syndrome.<sup>15</sup>

Hepatotoxicity observed in 17.1% to 42.8% of RTRs treated for TB because of additive toxic effects of immunosuppressive drugs particularly isoniazida.<sup>16</sup> There is no consensus on management of this side-effect. We introduced an alternative scheme with amikacin, ethambutol and levofloxacin and proceeded to the replacement of each drug for another of the initial scheme in order to avoid the aggressor. We decided to keep rifampicin, isoniazid, ethambutol and levofloxacin, with good results.

## CONCLUSION

This case puts in evidence the difficulty of diagnosis in RTR when common diseases present through uncommon manifestations delaying the diagnosis. Genitourinary TB must be considered in a RTR presenting with urinary symptoms. It also points out the difficulty on managing TB treatment and the necessity to monitor for hepatotoxicity when using rifamycin-containing regimen.

## REFERENCES

- Teixeira HC, Abramo C, Munk ME. Immunological diagnosis of tuberculosis: problems and strategies for success. *J Bras Pneumol* 2007;33:323-34. DOI: <http://dx.doi.org/10.1590/S1806-37132007000300015>
- Singh N, Paterson DL. Mycobacterium tuberculosis infection in solid-organ transplant recipients: impact and implications for management. *Clin Infect Dis* 1998;27:1266-77.
- Subramanian A, Dorman S; AST Infectious Diseases Community of Practice. *Am J Transplant* 2009;9:S57-62. DOI: <http://dx.doi.org/10.1111/j.1600-6143.2009.02894.x>
- Muñoz P, Rodríguez C, Bouza E. Mycobacterium tuberculosis infection in recipients of solid organ transplants. *Clin Infect Dis* 2005;40:581-7.
- Winthrop KL, Kubak BM, Pegues DA, Hufana C, Costamagna P, Desmond E, et al. Transmission of mycobacterium tuberculosis via lung transplantation. *Am J Transplant* 2004;4:1529-33.

6. Peters TG, Reiter CG, Boswell RL. Transmission of tuberculosis by kidney transplantation. *Transplantation* 1984;38:514-6.
7. Fiske CT, Griffin MR, Erin H, Warkentin J, Lisa K, Arbogast PG, et al. Black race, sex, and extrapulmonary tuberculosis risk: an observational study. *BMC Infect Dis* 2010;10:16.
8. Torre-Cisneros J, Doblas A, Aguado JM, San Juan R, Blanes M, Montejo M, et al.; Spanish Network for Research in Infectious Diseases. Tuberculosis after solid organ transplant: incidence, risk factors, and clinical characteristics in the RESITRA (Spanish Network of Infection in Transplantation) cohort. *Clin Infect Dis* 2009;48:1657-65.
9. Queipo JA, Broseta E, Santos M, Sánchez-Plumed J, Budía A, Jiménez-Cruz F. Mycobacterial infection in a series of 1261 renal transplant recipients. *Clin Microbiol Infect* 2003;9:518-25. DOI: <http://dx.doi.org/10.1046/j.1469-0691.2003.00532.x>
10. Boubaker K, Gargah T, Abderrahim E, Abdallah TB, Kheder A. Mycobacterium tuberculosis infection following kidney transplantation. *Biomed Res Int* 2013;2013:347103. DOI: <http://dx.doi.org/10.1155/2013/347103>
11. Eckardt KU, Kasiske BL. Kidney disease: improving global outcomes. *Nat Rev Nephrol* 2009;5:650-7. DOI: <http://dx.doi.org/10.1038/nrneph.2009.153>
12. Benito N, Sued O, Moreno A, Horcajada JP, González J, Navasa M, et al. Diagnosis and treatment of latent tuberculosis infection in liver transplant recipients in an endemic area. *Transplantation* 2002;74:1381-6. DOI: <http://dx.doi.org/10.1097/00007890-200211270-00006>
13. Sutherland I, Svandová E, Radhakrishna S. The development of clinical tuberculosis following infection with tubercle bacilli. 1. A theoretical model for the development of clinical tuberculosis following infection, linking from data on the risk of tuberculous infection and the incidence of clinical tuberculosis in the Netherlands. *Tubercle* 1982;63:255-68. PMID: 6763793 DOI: [http://dx.doi.org/10.1016/S0041-3879\(82\)80013-5](http://dx.doi.org/10.1016/S0041-3879(82)80013-5)
14. Bumbacea D, Arend SM, Eyuboglu F, Fishman JA, Goletti D, Ison MG, et al. The risk of tuberculosis in transplant candidates and recipients: a TBNET: consensus statement. *Eur Respir J* 2012;40:990-1013. DOI: <http://dx.doi.org/10.1183/09031936.00000712>
15. Sun HY, Munoz P, Torre-Cisneros J, Aguado JM, Lattes R, Montejo M, et al. Mycobacterium tuberculosis-associated immune reconstitution syndrome in solid-organ transplant recipients. *Transplantation* 2013;95:1173-81. DOI: <http://dx.doi.org/10.1097/TP.0b013e31828719c8>
16. Yee D, Valiquette C, Pelletier M, Parisien I, Rocher I, Menzies D. Incidence of serious side effects from first-line antituberculosis drugs among patients treated for active tuberculosis. *Am J Respir Crit Care Med* 2003;167:1472-7. PMID: 12569078 DOI: <http://dx.doi.org/10.1164/rccm.200206-626OC>