

Primary hyperoxaluria diagnosed after kidney transplantation: report of 2 cases and literature review

Hiperoxalúria primária diagnosticada após transplante renal: relato de dois casos e revisão da literatura

Authors

John Fredy Nieto Rios ¹
 Monica Zuluaga ²
 Lina Maria Serna Higuaita ³
 Adriana Florez ⁴
 Diana Carolina Bello-Marquez ⁵
 Arbey Aristizábal ¹
 Catalina Ocampo Kohn ¹
 Gustavo Adolfo Zuluaga ¹

¹ University of Antioquia, Pablo Tobón Uribe Hospital, Department of Nephrology and Renal Transplant, Medellín, Colombia.

² Universidad Pontificia Bolivariana, Department of Internal Medicine, Medellín, Colombia.

³ Universidade de Eberhard Karls, Instituto de Epidemiologia Clínica e Biometria Aplicada, Tuebingen, Alemanha.

⁴ Fundación Santafé de Bogotá, Department of Pathology, Medellín, Colombia.

⁵ Urogine, Department of Nephrology, Medellín, Colombia.

Submitted on: 03/14/2017.

Approved on: 05/18/2017.

Correspondence to:

John Fredy Nieto Rios.
 E-mail: johnfredynieto@gmail.com

DOI: 10.5935/0101-2800.20170081

ABSTRACT

Primary hyperoxaluria (PH) is a very rare genetic disorder; it is characterized by total or partial deficiency of the enzymes related to the metabolism of glyoxylate, with an overproduction of calcium oxalate that is deposited in different organs, mainly the kidney, leading to recurrent lithiasis, nephrocalcinosis and end stage renal disease (ESRD). In patients with ESRD that receive kidney transplantation alone, the disease has a relapse of 100%, with graft loss in a high percentage of patients in the first 5 years of transplantation. Three molecular disorders have been described in PH: mutation of the gene alanin glyoxalate aminotransferase (AGXT); glyoxalate reductase/hydroxy pyruvate reductase (GRHPR) and 4-OH-2-oxoglutarate aldolase (HOGA1). We present two cases of patients with a history of renal lithiasis who were diagnosed with primary hyperoxaluria in the post-transplant period, manifested by early graft failure, with evidence of calcium oxalate crystals in renal biopsy, hyperoxaluria, hyperoxalemia, and genetic test compatible; they were managed with proper diet, abundant oral liquids, pyridoxine, hydrochlorothiazide and potassium citrate; however, they had slow but progressive deterioration of their grafts function until they reached end-stage chronic renal disease.

Keywords: hyperoxaluria, primary; kidney failure, chronic; kidney transplantation; lithiasis; nephrocalcinosis.

RESUMO

A hiperoxalúria primária (HP) é um distúrbio genético muito raro, caracterizado por deficiência total ou parcial das enzimas relacionadas ao metabolismo do glioxilato, superprodução de oxalato de cálcio que se deposita em vários órgãos (principalmente os rins) resultando em litíase recorrente, nefrocalcinose e doença renal terminal (DRT). Nos pacientes com DRT que recebem transplante renal, a doença apresenta recidiva em 100% dos casos, com perda do enxerto nos primeiros cinco anos após o transplante num elevado percentual de pacientes. Três distúrbios moleculares foram descritos na HP: mutação dos genes da alanina-glioxilato aminotransferase (AGXT), glioxilato reductase/hidroxipiruvato reductase (GRHPR) e 4-OH-2-oxoglutarato aldolase (HOGA1). Apresentamos dois casos de pacientes com histórico de litíase renal diagnosticados com hiperoxalúria primária no período pós-transplante, manifestada na forma de perda precoce do enxerto com evidências de cristais de oxalato de cálcio na biópsia renal, hiperoxalúria, hiperoxalemia e testes genéticos compatíveis. Os pacientes foram tratados com abordagem nutricional, líquidos orais em abundância, piridoxina, hidroclorotiazida e citrato de potássio. Contudo, os pacientes apresentaram deterioração lenta e gradual da função do enxerto e evoluíram para doença renal terminal.

Palavras-chave: falência renal crônica; hiperoxalúria primária; litíase; nefrocalcinose; transplante de rim.

INTRODUCTION

Recurrent nephrolithiasis is associated with metabolism disorders of calcium, oxalate, uric acid or cysteine; or with recurrent urinary tract infections that favor struvite stones. Calcium calculi account

for 80% of lithiasis cases, half of which are associated with hyperoxaluria, which is most often secondary to digestive or eating disorders, and which rarely leads to end-stage chronic renal disease (ESRD); however, hyperoxaluria may also be

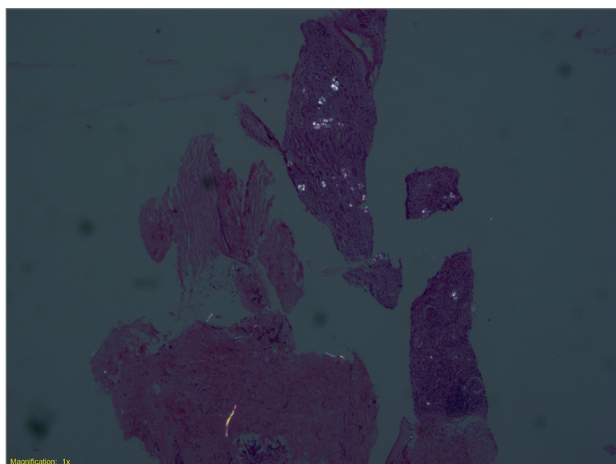
associated with genetic alterations in the metabolism of glyoxylate, which are termed primary hyperoxaluria (PH).^{1,2} Next we describe two cases of patients with recurrent nephrolithiasis that led to ESRD with subsequent relapse of lithiasis in their transplanted kidneys, and in whom PH was finally diagnosed.

CASE 1

A 33-year-old female patient, who first presented ESRD associated with coral calculi (*Staghorn calculi*) in 2002, requiring bilateral nephrectomy and to start hemodialysis. She was transplanted on February 5, 2004 in another institution, with subsequent graft loss due to unclear cause at 5 years, and to reenter to hemodialysis. Second transplant of cadaveric donor kidney on February 5, 2010 in our institution; she received induction with alemtuzumab plus metilprednisolona and maintenance with cyclosporine, mycophenolate and prednisone.

One year after transplantation, she presented a creatinine elevation, with renal biopsy that documented acute rejection of cellular Banff 1A and extensive deposits of oxalate in the interstitial tubule (Figure 1). For this reason, the rejection was treated with steroid boluses and conversion to tacrolimus; and there were performed complementary studies of renal oxalosis (Table 1), which led to the diagnosis of primary type 1 hyperoxaluria.

Figure 1. Case 1 - Histopathologic study of kidney biopsy, deposits of oxalate crystals can be seen (4X polarized light).



Extension studies found oxalate deposits in the bone marrow. Management was started with a diet low in oxalate, pyridoxine, potassium citrate and hydrochlorothiazide. She remained with graft nephropathy with slow but progressive deterioration; at her

last follow-up at 6 years, her creatinine was 4.8 mg/dl; she is in pre-dialysis stage and being evaluated for combined liver-kidney transplant.

CASE 2

A 53-year-old patient with a history of recurrent untreated nephrolithiasis who progressed to ESRD, which required to initiate dialysis in May 2008. A cadaveric donor kidney transplant was performed on July 9, 2010; the patient received induction with alemtuzumab plus methylprednisolone, maintenance with cyclosporine, mycophenolate and prednisone. In November 2010, the patient presented renal function impairment, and a graft biopsy showed Banff 2A acute cell rejection and extensive tubular damage, with presence of calcium oxalate crystals and microcalcifications (Figure 2).

The rejection was handled with pulses of methylprednisolone, thymoglobulin and conversion to tacrolimus; it was carried out a study of oxalosis with measurements of oxalate in urine and blood, which were elevated; and a genetic study, which was positive for the GRHPR gene. For this reason, it was diagnosed primary hyperoxaluria type 2 (Table 1).

In a study of extension for lower-limb chronic pain, it was diagnosed sensitive peripheral polyneuropathy, which is associated with this pathology. It was started management with diet low in oxalate, pyridoxine, potassium citrate and hydrochlorothiazide. The patient remained with creatinine of 1.9 mg/dl; at follow-up, the renal function became progressively deteriorated until a terminal stage, with reentry to dialysis in May 2015.

DISCUSSION

We present two cases of patients with a history of recurrent nephrolithiasis with progression to ESRD, with subsequent graft failure associated with extensive tubulo-interstitial infiltration by calcium oxalate crystals, which led us to investigate the cause, finally diagnosing PH.

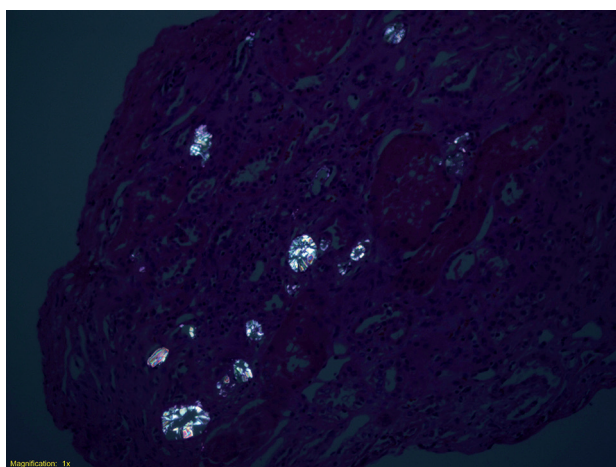
PH is an autosomal recessive genetic disorder, characterized by total or partial deficiency of the enzymes related to the metabolism of glyoxylate, with an excessive production of calcium oxalate that is deposited in different organs, mainly the kidney, leading to recurrent lithiasis, nephrocalcinosis and ESRD.^{1,2} Three molecular disorders are described: mutation of the enzyme gene alanin glioxalate aminotransferase

TABLE 1 LABORATORY RESULTS

Patient	Oxalate in blood (RV: lower than 30 $\mu\text{m/L}$)	Oxalate in 24-hour urine (RV: 3.6-38 mg)	Genetic Study
Number 1	38 $\mu\text{m/L}$	102.6 mg	Heterozygote for 2 variants of the gene AGTX: -c.731T > C (p.Ile244Thr): Variant with clear pathological meaning ³ -c.307G > A (p.Gly103Arg): Variant of unclear meaning, probably pathological, which had not been described.
Number 2	42 $\mu\text{m/L}$	150 mg	Gen GRHPR positive Heterozygote for 2 variants of the gene GRHPR: -c.478G > A (p.Gly160Arg) ⁴ -c.626C > T (p.Ser209Phe) ⁵

RV: reference value, μmL : micromoles per liter, AGTX: alanine glyoxalate aminotransferase, GRHPR: glyoxalate reductase/hydroxy pyruvate reductase.

Figure 2. Case 2 - Histopathologic study of kidney biopsy, deposits of oxalate crystals and microcalcifications can be seen (4X polarized light).



(AGTX) in 80% of cases; glyoxalate reductase/hydroxy pyruvate reductase (GRHPR) and 4-OH-2-oxoglutarate aldolase (HOGA1), each one in 10% of cases.^{1,2,6}

The most affected in PH is the urinary system, manifesting as recurrent nephrolithiasis and progressive deterioration of renal function. However, as the glomerular filtration rate falls below 40 ml/min, the compensation for serum oxalate levels is lost, reaching concentrations that exceed the threshold value of 30 micromoles/L, which triggers the accumulation of calcium oxalate in tissues such as the myocardium,

retina, blood vessels, joints, skin, nerve tissue and bone.

This can lead to arrhythmias, loss of visual acuity, ischemic phenomena, synovitis, livedo reticularis, calciphylaxis, neuropathy and bone deformities.² In the case of our patients, the initial commitment was exclusively renal, with progression to ESRD, which needed dialysis and later transplantation.

External factors that promote or inhibit the crystallization of oxalate influence on the phenotype, from hyperoxaluria without other changes in the urine, recurrent nephrolithiasis in adulthood, nephrocalcinosis, hematuria, urinary tract infection or progressive involvement, until it leads to ESRD; this explains that usually many of the patients with this disease remain undiagnosed, given the mild clinical presentation, with reports of its suspicion only when it is reached an ESRD;⁷ or after transplantation, when there is early graft dysfunction and evidence of birefringent oxalate crystals in the renal biopsy, as it was the case of our patients.⁸⁻¹⁴ In fact, frequently (30-60%, depending on the series), the diagnosis of PH is made after the relapse of oxalate deposits in renal transplantation, as it was described by Lorenzo *et al.*¹⁵ in a recent review on this topic.

The major question is why the patients who had a mild clinical course during the years prior to dialysis

developed a more severe manifestation with graft failure after transplantation. It's been suggested that the burden of serum and tissue oxalate migrates early in the graft; however, there are still doubts about the factors that influence on this, since the diagnosis of PH has only been described after a second renal transplant, as it was the case of our first patient.¹³

Kim *et al.*¹⁴ described the case of a woman with ESRD secondary to chronic interstitial nephritis, in whom the initial biopsy showed no crystals of calcium oxalate, nor did she have symptoms of renal lithiasis or systemic oxalosis, but she had deterioration of her renal function in the first 5 days post-transplant, evidencing deposits of calcium oxalate crystals in the tubules, and whose diagnosis of PH was later confirmed as due to a decrease in the enzymatic activity in the liver biopsy.

In addition, there is a post-transplant diagnosis of this condition without progression to graft failure, which is explained by a partial enzymatic defect with response to pyridoxine (cofactor of the enzyme AGXT); it has also been described the disappearance of renal oxalate deposits and their systemic values 18 months after therapy.¹⁶

Lorenz *et al.*¹⁷ reported 5 cases of patients with homozygous post-transplant hyperoxalosis for the G170R mutation of the AGXT gene, who had a sustained response to pyridoxine following isolated renal transplantation; only one presented graft failure, but after 13.9 years of follow-up. In the cases reported here, the patients had a progressive deterioration of their renal function, despite treatment with pyridoxine, which we associated with a late diagnosis.

The diagnosis is finally confirmed with oxaluria greater than 45 mg/day, 24 hour urine glycolate greater than 45 mg/day and oxalemia greater than 50 micromoles/L. Additional images can be obtained and a histological study be performed to evaluate the commitment of other organs, plus a genetic analysis of the AGXT, GRHPR, HOGA1 through sampling of peripheral blood DNA, in order to determine the specific mutation.

If the results are negative, it can be measured the activity of the enzyme in the hepatic tissue.^{2,6,8} In the first case described, two mutations of the AGXT gene were found, one of them was a classical mutation with clear pathological significance (compatible with PH type 1); the other one was of uncertain meaning, probably pathological, never reported before. In the

second case, two GRHPR gene mutations were found with uncertain meaning, but according to the literature, they were probably pathological, and taking into account the clinical context of the patient, there's no doubt that they were really pathological (compatible with PH type 2).

Treatment should be initiated immediately to decrease the deposit of urinary calcium oxalate, by increasing the fluid intake to more than 3L/m²/day; and avoiding crystallization by maintaining urinary pH between 6.2 and 6.8, with the use of potassium citrate at a dose of 0.1-0.15 g/kg a day; and using thiazide diuretics that decrease calciuria and increase urine volume.⁶

The only therapeutic strategy that impacts oxalate production, but only in PH type 1, is pyridoxine, starting with a dose of 5 mg/k/day, which is titrated to a maximum of 20 mg/k day. It is considered as adequate a decrease of oxaluria higher than 30% in three months of treatment with the maximum doses.^{1,6,11} Intermittent dialysis therapy is insufficient to purify all the oxalate produced. Similarly, isolated renal transplantation is a transient measure, because there is recurrence of the disease in the graft, and the only curative therapy is the combined liver and kidney transplantation, with reported survival rates of 80% at 5 years.^{2,6,16}

In accordance with the above, we consider that in all patients with a history of recurrent urolithiasis and nephrocalcinosis, a complete metabolic study in blood and urine should be performed, in order to determine the cause; in case of hyperoxaluria, a PH study must be included in the initial screening prior to renal transplantation, to establish early therapeutic measures that prevent the loss of renal graft.

CONCLUSION

PH is a genetic disorder of glyoxylate metabolism, which can lead to recurrent nephrolithiasis, with progression to ESRD and to early relapse of the graft, with damage to the graft itself. An early and timely diagnosis in the early stages of the disease may lead to the introduction of measures that may delay the progression of renal disease and avoid multisystemic compromise.

CONFLICTS OF INTEREST

All authors declare no conflict of interest with respect to the content of this article.

FUNDING SOURCE

Pablo Tobón Uribe Hospital, Medellín-Colombia.

REFERENCES

- Hoppe B. An update on primary hyperoxaluria. *Nat Rev Nephrol* 2012;8:467-75. <http://dx.doi.org/10.1038/nrneph.2012.113> DOI: <http://dx.doi.org/10.1038/nrneph.2012.113>
- Cochat P, Rumsby G. Primary hyperoxaluria. *N Engl J Med* 2013;369:649-58. <http://dx.doi.org/10.1056/NEJMra1301564> DOI: <http://dx.doi.org/10.1056/NEJMra1301564>
- von Schnakenburg C, Rumsby G. Primary hyperoxaluria type 1: a cluster of new mutations in exon 7 of the AGXT gene. *J Med Genet* 1997;34:489-92. DOI: <http://dx.doi.org/10.1136/jmg.34.6.489>
- Salido E, Pey AL, Rodriguez R, Lorenzo V. Primary hyperoxalurias: disorders of glyoxylate detoxification. *Biochim Biophys Acta* 2012;1822:1453-64. <http://dx.doi.org/10.1016/j.bbadis.2012.03.004> DOI: <http://dx.doi.org/10.1016/j.bbadis.2012.03.004>
- Hopp K, Cogal AG, Bergstralh EJ, Seide BM, Olson JB, Meek AM, et al. Phenotype-Genotype Correlations and Estimated Carrier Frequencies of Primary Hyperoxaluria. *J Am Soc Nephrol* 2015;26:2559-70. <http://dx.doi.org/10.1681/ASN.2014070698> DOI: <http://dx.doi.org/10.1681/ASN.2014070698>
- Cochat P, Hulton SA, Acquaviva C, Danpure CJ, Daudon M, De Marchi M, et al. Primary hyperoxaluria Type 1: indications for screening and guidance for diagnosis and treatment. *Nephrol Dial Transplant* 2012;27:1729-36. <http://dx.doi.org/10.1093/ndt/gfs078> DOI: <http://dx.doi.org/10.1093/ndt/gfs078>
- van Woerden CS, Groothoff JW, Wijburg FA, Waterham HR, Wanders RJ, Janssen MJ, et al. Primary hyperoxaluria remains undiagnosed in patients with hyperoxaluria and recurrent urolithiasis. *Clin Chem* 2007;53:1553-5. <http://dx.doi.org/10.1373/clinchem.2007.090688> DOI: <http://dx.doi.org/10.1373/clinchem.2007.090688>
- Naderi G, Tabassomi F, Latif A, Ganji M. Primary hyperoxaluria type 1 diagnosed after kidney transplantation: The importance of pre-transplantation metabolic screening in recurrent urolithiasis. *Saudi J Kidney Dis Transpl* 2015;26:783-5. <http://dx.doi.org/10.4103/1319-2442.160216> DOI: <http://dx.doi.org/10.4103/1319-2442.160216>
- Spasovski G, Beck BB, Blau N, Hoppe B, Tasic V. Late diagnosis of primary hyperoxaluria after failed kidney transplantation. *Int Urol Nephrol* 2010;42:825-9. <http://dx.doi.org/10.1007/s11255-009-9690-2> DOI: <http://dx.doi.org/10.1007/s11255-009-9690-2>
- Madiwale C, Murlidharan P, Hase NK. Recurrence of primary hyperoxaluria: an avoidable catastrophe following kidney transplant. *J Postgrad Med* 2008;54:206-8. <http://dx.doi.org/10.4103/0022-3859.41803> DOI: <http://dx.doi.org/10.4103/0022-3859.41803>
- Malakoutian T, Asgari M, Houshmand M, Mohammadi R, Aryani O, Mohammadi Pargoo E, et al. Recurrence of primary hyperoxaluria after kidney transplantation. *Iran J Kidney Dis* 2011;5:429-33.
- Alsuwaida A, Hayat A, Alwakeel JS. Oxalosis presenting as early renal allograft failure. *Saudi J Kidney Dis Transpl* 2007;18:253-6.
- Riksen NP, Timmers HJ, Assmann KJ, Huysmans FT. Renal graft failure due to type 1 primary hyperoxaluria. *Neth J Med* 2002;60:407-10. PMID: 12607592
- Kim HH, Koh HI, Ku BI, Lee HS. Late-onset primary hyperoxaluria diagnosed after renal transplantation presented with early recurrence of disease. *Nephrol Dial Transplant* 2005;20:1738-40. <http://dx.doi.org/10.1093/ndt/gfh889> DOI: <http://dx.doi.org/10.1093/ndt/gfh889>
- Lorenzo V, Torres A, Salido E. Primary hyperoxaluria. *Nefrologia* 2014;34:398-412. <http://dx.doi.org/10.3265/Nefrologia.pre2014.Jan.12335>
- Celik G, Sen S, Sipahi S, Akkin C, Tamsel S, Töz H, et al. Regressive course of oxalate deposition in primary hyperoxaluria after kidney transplantation. *Ren Fail* 2010;32:1131-6. <http://dx.doi.org/10.3109/0886022X.2010.509900> DOI: <http://dx.doi.org/10.3109/0886022X.2010.509900>
- Lorenz EC, Lieske JC, Seide BM, Meek AM, Olson JB, Bergstralh EJ, et al. Sustained pyridoxine response in primary hyperoxaluria type 1 recipients of kidney alone transplant. *Am J Transplant* 2014;14:1433-8. <http://dx.doi.org/10.1111/ajt.12706> DOI: <http://dx.doi.org/10.1111/ajt.12706>